


FATHER MULLER MEDICAL COLLEGE, MANGALORE

DEPARTMENT OF NEPHROLOGY

Innovation and creativity in teaching-learning

- Didactic lectures
- Case presentation (bed side)
- Subject Seminars
- Journal club
- Grand rounds
- Inter Department *Teaching*


Professor & HOD
Dept. of Nephrology
Father Muller Medical College Hospital
Mangaluru-575002

FATHER MULLER MEDICAL COLLEGE
DEPARTMENT OF OBSTETRICS & GYNAECOLOGY

Ref. No. : FMMC/OBG/ 25/2024

Date: 30.01.2024

CERTIFICATE

This is to certify that Dr. Prema D'Cunha has taken skill training session for U.G. batch on 19.10.2023.


SKILL TRAINING

Skill training session conducted for UG batch

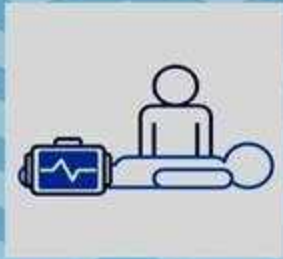DATE 19/10/2023

Topic Episiotomy suturing

Innovative model prepared by Dr Chethana , Dr Jyosna, Dr Prema

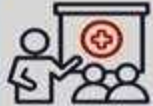
Dr. Deepa Kanagal
Professor & H.O.D.

ObGyn Video CLINICS



Topic - Exploring Hysteroscopy

**Presenter - Dr Divya
Facilitator - Dr Joylene**



**On Thursday 16 May 2024
2.30 pm
At OBG DEPT class and Labor**

DATES	9:00-10:00	10:00-11:00	11:00-12:00	2:30-3:30	3:30-4:30	ASSIGNMENT
22/02 THURS	INTRO TO DISEASING -P	HISTORY OF MEDICINE -P	WHAT IS A MUSEUM-RO	PHYSICIAN THROUGH THE AGES -P	MODERN MEDICINE -P	REFLECTION-What are your expectations from this elective
23/02/2024 FRI	CLAY MODELS -C	DOCKING -C	SWIT WITH PATIENTS	READING BETWEEN THE LINES NARRATIVE MEDICINE -CRISTINE	EXTRACT CP IN PATIENT	AUDIO CLIP first word- emotion memory the evokes
24/02 SAT	SWIT WITH PATIENTS	PROFESSOR NALISSA - JONATHAN	POETRY CP & LECTURE	ART OF OBSERVATION -VINAY		NARRATION AT THE DOCTOR'S
26/2 MON	SOCIAL SERVICE/ ORGAN DONATION -ROMAN MORIS		PRESENT	BOOKWALAH -DEENA	READING TO PRESENTS	REFLECTIONS- quality in you which makes you feel proud of yourself
27/02 TUE	BURNOUT -JYOSNA	NEUROSCIENCE DELIBERATION -P	ROLE PLAY	THEATRE OF THE OPPRESSED -P		Depict 'agony' and 'ecstasy' in your life
28/02 WED	VULNERABILITY -SHEERIN -P	FOR NO RHYME OR REASON ARUNA YADIVAL		LITERATURE -ANISSA		Are you a person in your life which you would like to cherish and share
29/02 THURS	BOTH SIDES NOW -OLIVER			AT THE MOVIES -SRISHANKER		SCENE NIGHT- WRITE ANY SCENE THAT SPEAKS TO YOU
01/03 FRI	SYMPATHY VS EMPATHY -RAHUL RAO		ROLE PLAY	MARGINALISATION- GENDER -ANISSA	SWIT & COPY READ -POORVA	VIDEO CLIP- LOOKING INTO THE EYES
02/03 SAT	TEAM BUILDING -LULU			CANCER -RICHAN GATEY	VIDEO -VISHI	Write a reflection on today's visit to the oncology ward
04/03 MON	REFLECTIVE WRITING -NAGESH		EXERCISE -ARUN	COMMUNICATION -ARCHANA BINT	SESSION WITH US -LINK TO IT -ADARSH	VIDEO CLIP- BREAKING BAD NEWS
05/03 TUE	SOCIAL MEDIA- MANJUNATH	CULTURAL COMPETENCE -P		MEDICALISATION/ PATERNALISM- CRISTINE		Discuss 1845 WT in any 10 mins
06/03 WED	DOCTOR-PATIENT RELATIONSHIP-TRUST-P		TRUST -ANUSHAAS ON	FINAL PROJECT	PRESENTATION	





ರಾಜೀವ್ ಗಾಂಧಿ ಆರೋಗ್ಯ ವಿಜ್ಞಾನಗಳ ವಿಶ್ವವಿದ್ಯಾಲಯ, ಕರ್ನಾಟಕ, ಬೆಂಗಳೂರು

RAJIV GANDHI UNIVERSITY OF HEALTH SCIENCES, KARNATAKA, BENGALURU
4th T Block, Jayanagar, Bengaluru – 560 041

RGU/ADV-RES/JOURNALS/22/2021-22

15-06-2023

NOTIFICATION

SUB:	The New Editorial Board members of RGUHS Journal of Allied Health Sciences.
REF:	Approval of Hon'ble Vice Chancellor dated: 07-06-2023

SL NO	Particulars	Designation
1.	Dr Archana Bhat, Associate Professor, Dept of Pathology, Father Muller Medical College Mangalore	Editor-in-Chief
2.	Dr Aravind Consultant General Surgeon, Cauvery Heart & Multispecialty Hospital Principal, Cauvery Institute of Health Sciences, Mysore	Assistant Editor
3.	Dr. Manjunath J Professor & Head Department of Nephrology Dept of Pathology, Father Muller Medical College, Mangalore	Assistant Editor
4.	Prof Rajesh Shenoy Director, Padmashree group of Institutions Principal, Padmashree institute of Medical Lab Technology, Bangalore.	Member
5.	Dr. Girish K S Associate Professor Department of Biochemistry Bowring & Curzon Medical College Research Institute, Bangalore	Member
6.	Dr. Priyadarshini A Padaki Assistant Professor Department of Microbiology St John's Medical College, Bangalore	Member
7.	Mrs. Minakshi Sharma Assistant Professor, Orthotics & Prosthetics Mobility India Rehabilitation research & Training Centre, Bangalore	Member

8.	Mrs. PratijnaSuhasini G R Principal Mangala College of Allied Health Sciences Mangalore	Member
9.	Mrs. Supreeta Castellino Department of Hospital Administration St Johns Medical College, Bangalore	Member
10.	Mr. Avinash Prabhu Optometry division, AHS M.S. Ramaiah University of Applied Sciences,Bangalore	Member

As per the decision of Hon'ble Vice Chancellor vide cited reference the tenure of the above mentioned editorial board is two years up to 31-05-2025.


REGISTRAR


To,
All the members of RGUHS Journal of Allied Health Sciences.
Copy to,

- 1.The members of the Syndicate, RGUHS.
- 2.PA to Vice-chancellor/Registrar/Registrar (Evaluation)/Finance Officer, RGUHS.

Case Based Learning

A 35 year old female Sandhya was a banker by occupation. She complained of unsteadiness while walking. She also felt weak to carry out her daily routine activities. She was a strict vegan.

1. What are the causes of unsteadiness?
2. At the end of history, what condition do you think Sandhya is suffering from?

On examination, she was pale, rhomberg's sign was positive. She had bilateral extensor planter response with absent ankle jerk . Her laboratory investigations revealed anemia, macrocytic RBCs with hypersegmented neutrophils. A specific blood test was asked based on these reports. She was started on injections for her clinical condition. On follow up, she felt better and her symptoms had significantly improved.

1. What is your diagnosis?
2. What are the common causes for this condition?
3. Mention other causes of macrocytic RBCs.
4. How will you treat her?
5. How will you assess the response to treatment?

OBJECTIVES:

At the end of the session, the student should be able to:

1. Enumerate the causes for Megaloblastic anemia.
2. Discuss the clinical features of Megaloblastic anemia
3. List the differential diagnosis
4. Discuss the management

CASE BASED LEARNING

A 35 year old gentleman Mr. Raju, hailing from Bantwal, working in a poultry farm presents to you with complaints of fever of 3 weeks duration. Fever is associated with generalized myalgia, loss of appetite and weight loss. He also complains of left hip joint pain due to which he has difficulty in walking. On taking a detailed history, patient reports of having fever with myalgia one and half month ago , which lasted for 2 weeks and subsided. Following this he was afebrile for 1 week after which he again started developing fever spikes.

On examination :

PR – 100/min , BP – 120/80 mm Hg

RR -22/min Temperature – 100° F

On system examination , liver palpable 2 cm below right costal margin , non tender, firm in consistency .

Investigation :

HB - 12 gm%

TC - 8,800/ cu.mm

Neutrophils - 45%

Lymphocytes - 50%

Eosinophils - 4%

Monocytes - 1%

Basophils - 0%

ESR - 30mm/hr

Liver function test

T. bilirubin – 1mg/dl, unconjugated bilirubin – 0.8 mg/ dl conjugated bilirubin - 0.2 mg/dl, AST -42 IU/l , ALT – 44 IU/l , ALP – 100 IU /l , S. Total protein - 7.2 gm/dl , S. Albumin – 4 gm/dl, S. Globulin - 3.2gm dl

1. What are the deferential diagnosis to be considered
2. What are the investigations to be performed to confirm the diagnosis
3. What are the other clinical Manifestations of this condition and how do you evaluate
4. Drugs used in treatment of this clinical condition

Case Based Learning

A 23 year old Mohan, a hostel resident presented with 5 days history of fever, abdominal pain and vomiting. On examination mild icterus + tender hepatomegaly +

- A) What possibilities would you like to consider?
- B) Mention causes of tender hepatomegaly.

His lab report revealed total count $12,000/\text{mm}^3$ normal renal parameters' liver function tests showed TB :3.5mg%, DB :2 mg%, TP:6.5 g/dl, Serum albumin: 4g/dl, globulin 2.5g/dl, AST :2500IU, ALT :3000 IU

PT normal.

- a) What do you conclude based on the above reports?
- b) What further tests would you like to ask for?
- c) Mention other causes of marked elevation of liver enzymes(>500 IU)
- d) What are the complications of the condition?
- e) How will you treat this condition?

Objectives :

At the end of the session the student should be able to

1. Enumerate the causes for acute hepatitis
2. List the clinical features of acute hepatitis
3. Enumerate the relevant investigations
4. Discuss the treatment for acute hepatitis
5. List the preventive measures for acute hepatitis

The above topic of acute hepatitis was taught to 8th term students on 13.04.2016 as per the above protocol. At the end of the session the students found it better than the traditional didactic lectures. I planned to implement case based learning for my theory classes in future.

A 18 year old girl presented with paraplegia, ataxia, fever and fatigue which had started a few months back and which was getting worse since the past 2 weeks. Examination of the sensory system showed loss of pain, touch, temperature, vibration and joint position sense. The limbs were found to be spastic. Peripheral smear showed the presence of macrocytic anemia with hyper segmented neutrophils. Work up revealed that the patient had features suggestive of tuberculosis involving the ileocecal junction.

- 1) what is your diagnosis for the patient and substantiate?
- 2) Enumerate various causes that can cause the nutritional deficiency in question?
- 3) What is the schillings test and describe in detail?
- 4) How do you treat the condition?
- 5) what are the differential diagnoses for the same?

A forty year old female presented with history of severe pain in the left forearm and ankle following a trivial injury. The patient had a swelling in the left leg and also complained that she had pain in the same leg and on movement of the ankle since the past 2 years. Radiography showed the presence of pathological fractures in the radius and ulna and an expansile lytic lesion in the region of the ankle. X ray skull was suggestive of a "pepper pot" appearance. Radiograph of the hands showed osteopenia with expansile lytic lesions in the metacarpals. USG neck showed a 1.5x1.5 hypoechoic lesion on the posterior aspect of the thyroid gland. Labs revealed Calcium-12mg/dl, Alkaline phosphatase 727u/l, Serum parathyroid hormone -1265pg/ml.

- 1) What is your diagnosis for the patient?
- 2) What are the differential diagnoses for the patient?
- 3) How can we best treat the patient?
- 4) Describe the complications of hypocalcemia and hypercalcemia?
- 5) Describe calcium metabolism in detail?
- 6) Describe the treatment modalities available for the treatment of osteoporosis?

A 20-year-old female patient was admitted to the hospital for persistent vomiting, diarrhea, and nausea. She had Crohns disease since age 9 and was on chronic total parenteral nutrition (TPN). Two months before admission, multivitamin infusion (MVI) was discontinued in the TPN because of the shortage of its supply. An oral multivitamin tablet was substituted instead. Patient presented with altered sensorium, had abnormal eye movements and an unsteady gait. Fat stores and muscle tissue were decreased. Her respiratory rate was 24/min. Her blood pressure, while she was standing, was 105/65 mmHg. Liver tests were normal. The serum lactate concentration was substantially increased. Magnetic resonance imaging (MRI) showed several areas of abnormally high signal on T2- weighted images in the brainstem, thalamus, and mamillary bodies.

- 1) what is your possible diagnosis for the patient and substantiate?
- 2) Why are the fat stores and muscle tissue decreased in this patient?
- 3) Which metabolic enzyme is affected with regards to the vitamin in question? How and why?
- 4) What are the cardiovascular manifestations?
- 5) How do you treat the condition?

A 35 year old female Sandhya was a banker by occupation. She complained of unsteadiness while walking. She also felt weak to carry out her daily routine activities. She was a strict vegan. On examination, she was pale, rhomberg's sign was positive. She had bilateral extensor planter response with absent ankle jerk . Her laboratory investigations revealed anemia, macrocytic RBCs with hypersegmented neutrophils. A specific blood test was asked based on these reports. She was started on injections for her clinical condition. On follow up, she felt better and her symptoms had significantly improved.

CASE BASED LEARNING

A 35 year old gentleman Mr. Raju, hailing from Bantwal, working in a poultry farm presents to you with complaints of fever of 3 weeks duration. Fever is associated with generalized myalgia, loss of appetite and weight loss. He also complains of left hip joint pain due to which he has difficulty in walking. On taking a detailed history, patient reports of having fever with myalgia one and half month ago , which lasted for 2 weeks and subsided. Following this he was afebrile for 1 week after which he again started developing fever spikes.

On examination :

PR – 100/min , BP – 120/80 mm Hg

RR -22/min Temperature – 100° F

On system examination , liver palpable 2 cm below right costal margin , non tender, firm in consistency .

Investigation :

HB - 12 gm%

TC - 8,800/ cu.mm

Neutrophils - 45%

Lymphocytes - 50%

Eosinophils - 4%

Monocytes - 1%

Basophils - 0%

ESR - 30mm/hr

Liver function test

T. bilirubin – 1mg/dl, unconjugated bilirubin – 0.8 mg/ dl conjugated bilirubin - 0.2 mg/dl, AST -42 IU/l , ALT – 44 IU/l , ALP – 100 IU /l , S. Total protein - 7.2 gm/dl , S. Albumin – 4 gm/dl, S. Globulin - 3.2gm dl

1. What are the deferential diagnosis to be considered
2. What are the investigations to be performed to confirm the diagnosis
3. What are the other clinical Manifestations of this condition and how do you evaluate
4. Drugs used in treatment of this clinical condition

Case Based Learning

A 23 year old Mohan, a hostel resident presented with 5 days history of fever, abdominal pain and vomiting. On examination mild icterus + tender hepatomegaly +

- A) What possibilities would you like to consider?
- B) Mention causes of tender hepatomegaly.

His lab report revealed total count $12,000/\text{mm}^3$ normal renal parameters' liver function tests showed TB :3.5mg%, DB :2 mg%, TP:6.5 g/dl, Serum albumin: 4g/dl, globulin 2.5g/dl, AST :2500IU, ALT :3000 IU

PT normal.

- a) What do you conclude based on the above reports?
- b) What further tests would you like to ask for?
- c) Mention other causes of marked elevation of liver enzymes(>500 IU)
- d) What are the complications of the condition?
- e) How will you treat this condition?

Objectives :

At the end of the session the student should be able to

1. Enumerate the causes for acute hepatitis
2. List the clinical features of acute hepatitis
3. Enumerate the relevant investigations
4. Discuss the treatment for acute hepatitis
5. List the preventive measures for acute hepatitis

The above topic of acute hepatitis was taught to 8th term students on 13.04.2016 as per the above protocol. At the end of the session the students found it better than the traditional didactic lectures. I planned to implement case based learning for my theory classes in future.

Date: 14.04.2016

From,

Dr. Akshatha Rao Aroor
Associate Professor
Medicine

To ,

The HOD
Department of Medicine

Respected sir,

Subject : Implementation of case based learning to final year MBBS students.

This is to inform you that I have implemented case based learning on the topic "acute hepatitis" to 8th term students on 13.04.2016. There was active participation from the students and they found this method to be beneficial. Details of the case based learning are enclosed herewith.

Thanking you,

Dr. Akshatha Rao
Associate Professor

A 18 year old girl presented with paraplegia, ataxia, fever and fatigue which had started a few months back and which was getting worse since the past 2 weeks. Examination of the sensory system showed loss of pain, touch, temperature, vibration and joint position sense. The limbs were found to be spastic. Peripheral smear showed the presence of macrocytic anemia with hyper segmented neutrophils. Work up revealed that the patient had features suggestive of tuberculosis involving the ileocecal junction.

- 1) what is your diagnosis for the patient and substantiate?
- 2) Enumerate various causes that can cause the nutritional deficiency in question?
- 3) What is the schillings test and describe in detail?
- 4) How do you treat the condition?
- 5) what are the differential diagnoses for the same?

A forty year old female presented with history of severe pain in the left forearm and ankle following a trivial injury. The patient had a swelling in the left leg and also complained that she had pain in the same leg and on movement of the ankle since the past 2 years. Radiography showed the presence of pathological fractures in the radius and ulna and an expansile lytic lesion in the region of the ankle. X ray skull was suggestive of a "pepper pot" appearance. Radiograph of the hands showed osteopenia with expansile lytic lesions in the metacarpals. USG neck showed a 1.5x1.5 hypoechoic lesion on the posterior aspect of the thyroid gland. Labs revealed Calcium-12mg/dl, Alkaline phosphatase 727u/l, Serum parathyroid hormone -1265pg/ml.


- 1) What is your diagnosis for the patient?
- 2) What are the differential diagnoses for the patient?
- 3) How can we best treat the patient?
- 4) Describe the complications of hypocalcemia and hypercalcemia?
- 5) Describe calcium metabolism in detail?
- 6) Describe the treatment modalities available for the treatment of osteoporosis?

A 20-year-old female patient was admitted to the hospital for persistent vomiting, diarrhea, and nausea. She had Crohns disease since age 9 and was on chronic total parenteral nutrition (TPN). Two months before admission, multivitamin infusion (MVI) was discontinued in the TPN because of the shortage of its supply. An oral multivitamin tablet was substituted instead. Patient presented with altered sensorium, had abnormal eye movements and an unsteady gait. Fat stores and muscle tissue were decreased. Her respiratory rate was 24/min. Her blood pressure, while she was standing, was 105/65 mmHg. Liver tests were normal. The serum lactate concentration was substantially increased. Magnetic resonance imaging (MRI) showed several areas of abnormally high signal on T2- weighted images in the brainstem, thalamus, and mamillary bodies.

- 1) what is your possible diagnosis for the patient and substantiate?
- 2) Why are the fat stores and muscle tissue decreased in this patient?
- 3) Which metabolic enzyme is affected with regards to the vitamin in question? How and why?
- 4) What are the cardiovascular manifestations?
- 5) How do you treat the condition?

Surgical Training for Post Graduates using Goat Eye:

In ophthalmic PG training doing surgeries is a prerequisite. As it is a microsurgery there is a long learning curve attached to it. It is important for the postgraduates to develop hand eye coordination using the microscope. Hence we use the help of goat eyes to help the PG's develop hand eye coordination and practice basic surgical steps on the goat's eye using the microscope before they venture on to real patients eyes.



Dr. Nelly Nazareth

Professor & HOD

Dept. of Ophthalmology

